



Published by  
Department of Dermatology and  
Venereology, Universitas Udayana



## Large acrochordon of labium majora: an unusual location

Yoana Fransiska Wahyuning Christi<sup>1</sup>, Hamidah Luthfidyaningrum<sup>1</sup>, Dwi Murtiastutik<sup>1</sup>,  
Affif Nurul Hidayati<sup>1</sup>, Septiana Widyantari<sup>1</sup>, Astindari<sup>1</sup>, Maylita Sari<sup>1</sup>,  
Irmadita Citrashanty<sup>1\*</sup>

### ABSTRACT

**Background:** Acrochordon is a soft, round or oval, pedunculated papilloma that can be tan or brown. Although acrochordons most commonly appear in the neck, axilla, and groin, they can also occur in unusual sites, such as penis, vulva, and perineum. Most of the lesions are small pedunculated papules or nodules approximately 2–6 mm, but rarely, particularly on the lower section of the trunk, large pedunculated acrochordons can be found. Here, we present a large acrochordon on the labium majora.

**Case:** A 25-year-old woman came to an outpatient clinic because of a mass on her right labium majora since she gave birth three years prior. The size of the mass started relatively small but has grown significantly over time. From a dermatological examination of the external genitalia region, there was a solitary, pedunculated, skin-colored mass measuring 10 × 3 cm attached to the right labium majora. There was no redness, ulceration, bleeding or discharge. Cautery excision with local anesthetic was performed to remove the mass. The histopathological examination of the specimen revealed polypoidal tissue lined by an epidermal layer, proliferation and dilation of capillaries containing erythrocytes in the dermis layer, and mild infiltration of lymphocytes and histiocytes. No evidence of malignancy.

**Conclusion:** We report an unusual location of acrochordon presenting with large size. Due to its atypical presentation, it may be confused with a malignancy, necessitating a pathological test. Total excision of the mass is recommended.

**Keywords:** Acrochordon, cautery excision, labium majora, large.

**Cite This Article:** Christi YFW, Luthfidyaningrum H, Murtiastutik D, Hidayati AN, Widyantari S, Astindari, Sari M, Citrashanty I, Large acrochordon of labium majora: an unusual location. *Bali Dermatology Venereology and Aesthetic Journal*. 2023;6(1):17-19. DOI: 10.51559/93p62v41

<sup>1</sup>Department of Dermatology and Venereology, Faculty of Medicine, Universitas Airlangga/Dr. Soetomo General Academic Hospital, Surabaya, East Java, Indonesia.

\*Corresponding author:  
Irmadita Citrashanty;  
Department of Dermatology and Venereology, Faculty of Medicine, Universitas Airlangga/Dr. Soetomo General Academic Hospital, Surabaya, East Java, Indonesia;  
irmadita@gmail.com

Submitted: 2023-01-11  
Accepted : 2023-03-08  
Published: 2023-06-30

## INTRODUCTION

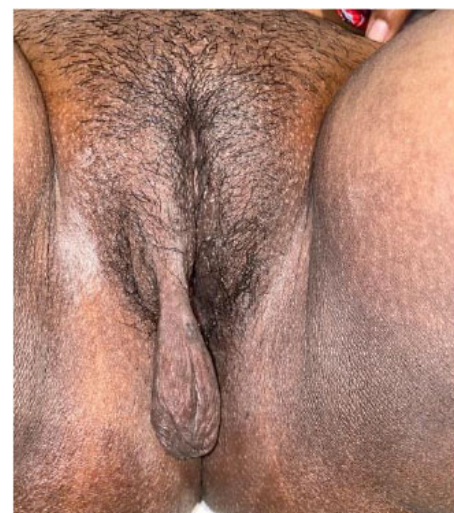Acrochordon is a soft, round or oval, pedunculated papilloma that can be tan or brown. It is also known as skin tag, cutaneous papilloma, or soft fibroma. They are prevalent, often run in families, and equally impact men and women, especially those over the age of 50.<sup>1,2</sup>

Although acrochordons most commonly appear in the neck, axilla, and groin, they can also appear in other, more out-of-the-ordinary locations. The penis, the vulva, and the perineum have all been recorded as unusual sites. Rarely, especially on the lower trunk, larger pedunculated acrochordons might appear. Most lesions are small pedunculated papules or nodules between 2 and 6 mm in size.<sup>2-4</sup> We present a case of a large acrochordon located on the labium majora for its unusual location.

## CASE DESCRIPTION

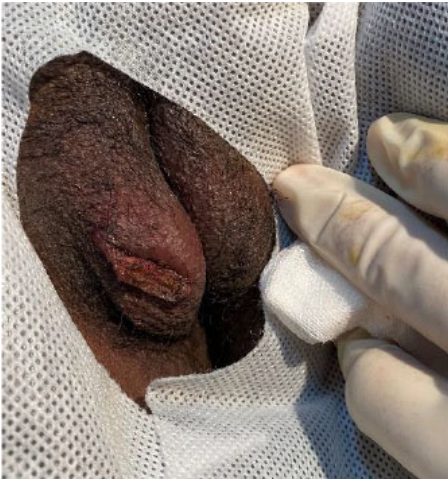A 25-year-old woman came to an outpatient clinic because of a mass on her right labium majora ever since she gave birth three years prior. The size of the mass started relatively small but has grown significantly over time. The patient grew concerned about the rising size of the mass and experiencing discomfort from friction caused by walking. There was no pruritus, pain, redness, ulceration, bleeding, discharge, or sudden enlargement. There was no history of the same complaint before, and a similar lesion in other body areas was denied. The patient was overweight (body mass index 26.2 kg/m<sup>2</sup>).

From a dermatological examination of the external genitalia region, there was a solitary, pedunculated, skin-colored mass measuring 10 × 3 cm attached to the right labium majora (Figure 1). There was no redness, ulceration, bleeding or discharge.

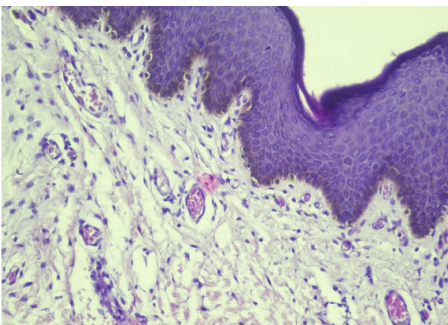


**Figure 1.** Pedunculated mass on labium majora measuring 10 x 3 cm.

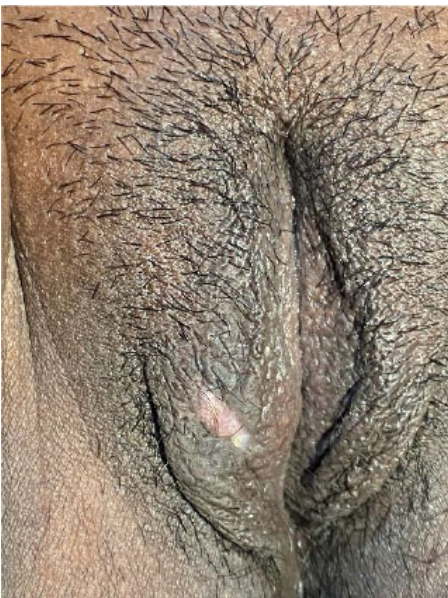All the routine examinations were within normal limits. Results from lipid profile and blood glucose level check were within the usual range.



**Figure 2.** Immediate after cautery excision.



**Figure 3.** Polypoidal tissue lined by epidermal layer. Hematoxylin and eosin, magnification 20 times.



**Figure 4.** Three weeks after cautery excision.

Cautery excision under local anesthesia was performed to remove the mass. We used a povidone-iodine solution and 70% alcohol to disinfect the lesion and the surrounding area. The lesion was anesthetized by injecting 2% lidocaine hydrochloride into the base of the pedicle. The pedicle was clamped with forceps at its base and then cut with electrocautery parallel to the skin surface (Figure 2). Electrodesiccation and pressure dressing were used to stop the bleeding.

The histopathological examination of the specimen revealed polypoidal tissue lined by an epidermal layer, proliferation and dilation of capillaries containing erythrocytes in the dermis layer, and mild infiltration of lymphocytes and histiocytes (Figure 3). No evidence of malignancy. Clinical and histological findings led to the diagnosis of a large acrochordon of labium majora.

### DISCUSSION

Acrochordon is a benign lesion of loose fibrous tissue, often found in skin folds. They are prevalent, often run in families, and equally impact men and women, especially those over the age of 50.<sup>2,5</sup> They have been linked to several metabolic disorders including hypertension, diabetes mellitus, dyslipidemia, obesity, and cardiovascular diseases.<sup>6</sup> There is a substantial connection of acrochordon with triglycerides, low-density lipoproteins, very low-density lipoproteins, and leptin levels, according to a case-control study performed in a tertiary care hospital in South India. Other parameters, such as high-density lipoproteins, body mass index and glucose levels, were altered but were not statistically significant.<sup>7</sup> However, in this case, the patient was not obese, and the lipid profile was within normal limits.

Most acrochordons are small, soft, pedunculated papules or nodules that can be any color, from skin-colored to hyperpigmentation.<sup>2,3</sup> Large lesions could develop due to the proliferation of mesenchymal cells within the hormonally sensitive subepithelial stromal layer of the lower genital tract.<sup>8</sup> These tumors are typically asymptomatic, but sometimes they may be inflamed from the friction, which restricts their blood supply and

causes partial or complete necrosis.<sup>2,3</sup> In this patient, the lesion was a solitary, pedunculated, skin-colored mass with an unusually large size, reaching approximately 10 × 3 cm in height and width. There was no sign of inflammation.

Acrochordons can appear single or in groups, most frequently found on the neck, eyelids, and intertriginous areas (groin, inframammary, axillae).<sup>1</sup> It can happen in uncommon places on the body, like the penis, vulva, and perineum.<sup>3,9,10</sup> Skin tags over the labia majora have only infrequently been documented in the literature.<sup>3,4,8,11-13</sup>

Most diagnoses are made clinically. They don't typically need to be sent in for microscopic analysis. The clinical symptoms of these conditions may, however, overlap with those of malignant neoplasms, and a histopathological examination may be helpful for confirmation, particularly in uncommon cases. Malignancies to consider include squamous cell and basal cell carcinoma.<sup>2,4</sup> Acrochordons may occasionally thrombose and turn black or purple, which should cause worry because it could be melanoma. According to published research, the acrochordon's histological findings show a flattened epithelium overlies a dermis filled with loosely arranged collagen fibers and dilated capillaries and lymphatics.<sup>2,13</sup> As in this patient, The histopathological examination of the specimen revealed polypoidal tissue lined by an epidermal layer, there are proliferation and dilation of capillaries containing erythrocytes in the dermis layer, mild infiltration of lymphocytes and histiocytes. No evidence of malignancy.

Small acrochordons can be treated using various techniques, including electrodesiccation, cryotherapy, or laser surgery, but bigger lesions require surgical excision.<sup>3</sup> Some published case reports of large acrochordons on the vulva region performed surgical excision with primary closure, using several methods such as local anesthesia, spinal anesthesia, or general anesthesia.<sup>3,4,8,11-13</sup> In this patient, we performed cautery excision under local anesthesia, with secondary closure. The lesion was fully removed, and a follow-up three weeks later revealed a small scar that the patient found tolerable (Figure 4).

## CONCLUSION

We report an unusual location of acrochordon presenting with large size. Due to its atypical presentation, it may be confused with a malignancy, necessitating a pathological test. Total excision of the mass is recommended.

## CONFLICT OF INTEREST

The authors declare that there is no conflict of interest regarding the publication of this article.

## FUNDING

Any source does not fund this article.

## AUTHOR CONTRIBUTIONS

Author YFWC constructed the concepts, searched for literature, data collection, and main writer, and edited the manuscript. Author HL searched for literature, collected data, and prepared and edited the manuscript. Authors DM, ANH, SW, A,

and MS reviewed the manuscript. Author IC constructed concepts and reviewed the manuscript.

## REFERENCES

1. Wolff K, Johnson R, Saavedra A, et al. Fitzpatrick's color atlas and synopsis of clinical dermatology, 8th Edition. New York: McGraw-Hill Education, 2017:89-93
2. Vincent KD, Abramovits W. Acrochordons (Skin Tags) BT - Dermatological Cryosurgery and Cryotherapy. In: Abramovits W, Graham G, Har-Shai Y, et al, editors. London: Springer London, pp.595-597.
3. Amala S, Kumari L, Mirunalini M. A giant acrochordan over labia majora: an unusual location of skin tag. IOSR J Dent Med Sci. 2017;16:8-10.
4. Zebitay A, Kahramanoglu I, Ilhan O, et al. Unusually large skin tag of labium majus. Open J Obstet Gynecol. 2014;4:699-702.
5. Madan V, Lear JT. Benign Keratinocytic Acanthomas and Proliferations. In: Rook's Textbook of Dermatology, Ninth Edition, pp.1-9.
6. Uzuncakmak TK, Akdeniz N, Karadag AS. Cutaneous manifestations of obesity and the metabolic syndrome. Clin Dermatol. 2018;36:81-88.
7. Wali V, Wali V. Assessment of various biochemical parameters and BMI in patients with skin tags. J Clin Diagnostic Res. 2016;10:9-11.
8. Garg S, Baveja S. Giant acrochordon of labia majora: An uncommon manifestation of a common disease. J Cutan Aesthet Surg. 2015;8:119-120.
9. Emir L, Ak H, Karabulut A, et al. A huge unusual mass on the penile skin: Acrochordon. Int Urol Nephrol. 2004;36: 563-565.
10. Bord A, Valsky D V, Yagel S. Prenatal sonographic diagnosis of congenital perineal skin tag: case report and review of the literature. Prenat Diagn. 2006; 26: 1065-1067.
11. Gupta G, Sinha R, Pandey S, et al. A giant skin Tag over labium majus: An unusual location of skin tag. Egypt Dermatology Online J. 2012; 8: 1-6.
12. Ma H, Xia Y, Yin S, et al. Giant skin tag on the labium majorum. Int J Women's Dermatology. 2015; 1: 175-176.
13. Kassinove A, Raam R. Acrochordon of the Labia. J Emerg Med. 2013; 44: e361-e362.



This work is licensed under a Creative Commons Attribution