



Published by  
Department of Dermatology and  
Venereology, Universitas Udayana

## Discrepancy of PCR and serologic test on genital herpes: a case report



Jhauharina Rizki Fadhilla<sup>1\*</sup>, Wresti Indriatmi<sup>1</sup>, Hanny Nilasari<sup>1</sup>, Yudo Irawan<sup>1</sup>

<sup>1</sup>Dermatology and Venereology  
Department, Faculty of Medicine,  
University of Indonesia/National  
Central General Hospital dr. Cipto  
Mangunkusumo, Jakarta

\*Corresponding to :

Jhauharina Rizki Fadhilla;  
Dermatology and Venereology  
Department, Faculty of Medicine,  
University of Indonesia/National  
Central General Hospital dr. Cipto  
Mangunkusumo, Jakarta  
Phone: 08129735043;  
jhauharina.rizki@gmail.com

Received: 2021-03-28  
Accepted: 2021-05-27  
Published: 2021-06-01

### ABSTRACT

**Background:** Laboratory investigation for genital herpes (GH) includes serologic tests and polymerase chain reaction (PCR) with different sensitivity and specificity; occasionally, the results are not conclusive. Clinical symptoms are often atypical. We report a case of GH in HIV-infected patients with a non-reactive serologic test but positive PCR.

**Case Description:** A 29-years old HIV-positive man presented with multiple painful shallow ulcers with pus on his penis in the last five days. PCR examination showed a positive result, whereas anti-HSV 1 IgM, anti-HSV 2 IgM, anti-HSV 2 IgG, VDRL, and TPHA were negative. The anti-HSV- 1 IgG result was reactive with a CD4 value of 122 cells/ $\mu$ L. The patient was given Acyclovir 3x400 mg for ten days and Co-amoxiclav 3x625 mg for seven days. Significant improvement was obtained, and the pain subsided.

**Conclusion:** Clinical features of GH in infected HIV patients are often atypical and resemble other genital ulcers, thus requiring additional investigations. The serologic test may sometimes present a false negative, whereas PCR is much more sensitive and specific, nearing 100%. In patients with HIV infection, GH diagnosis at an early stage can shorten the course of the disease and prevent complications.

**Keywords:** genital herpes, herpes simplex virus, PCR, serology

**Cite This Article:** Fadhilla, J.R., Indriatmi, W., Nilasari, H., Irawan, Y. 2021. Discrepancy of PCR and serologic test on genital herpes: a case report. *Bali Dermatology and Venereology Journal* 3(2): 8-11. DOI: 10.15562/bdv.v4i1.49

### INTRODUCTION

Genital herpes (GH) is a sexually transmitted disease with approximately 417 million people worldwide in 2015.<sup>1</sup> Genital herpes patient visits have also increased in the Sexually Transmitted Infection (STI) Division of the Dermatology and Venereology outpatient clinic, Cipto Mangunkusumo Hospital (RSCM). In 2017, GH visits were 1.7% and increased to 4.7% in 2018 and 4.3% (2019). There are two types of herpes simplex virus (HSV) that cause GH, HSV-1, and HSV-2. Clinical symptoms due to HSV-1 are milder and recurrent less frequently, whereas HSV-2 infection often causes recurrences.<sup>1</sup> HSV-1 condition usually occurs in men who have sex with men (MSM).<sup>1,2</sup> In immunocompromised patients, HSV infection can cause GH with atypical lesion manifestations and a protracted disease course. HSV viral

shedding is increased in patients with HIV infection. Antiretroviral therapy (ARV) can reduce the recurrence and severity of GH.<sup>2</sup> Investigations for GH are essential to assist in the diagnosis of GH, but some tests can give inconclusive results. We report a case of GH in an HIV-infected patient who was positive on PCR, whereas serologic tests were non-reactive.

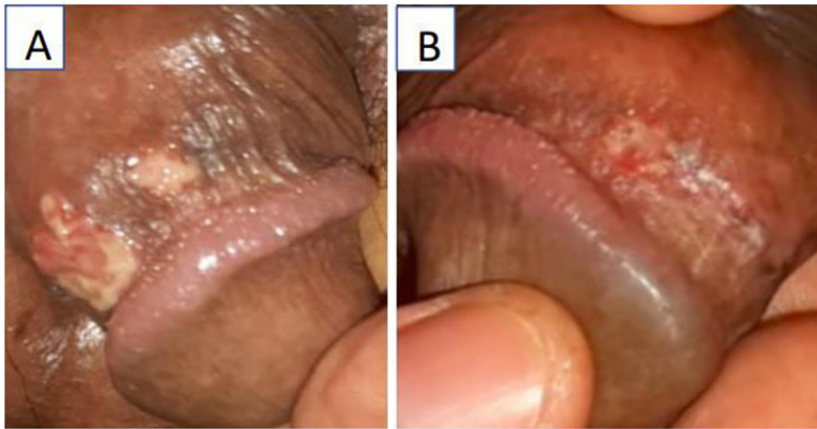
### CASE REPORT

A 29 years old man, self-employed, Timorese, Indonesian citizen, Christian, college-educated, came to the STI Division of Dermatology and Venereology outpatient, RSCM, on Feb 14, 2020, with a complaint of a painful, burning sore on the penis since five days ago. Initially, there was a wound on the right side of the penis, then around the top of the penis covered by the foreskin. The patient did not know whether there were vesicles before the

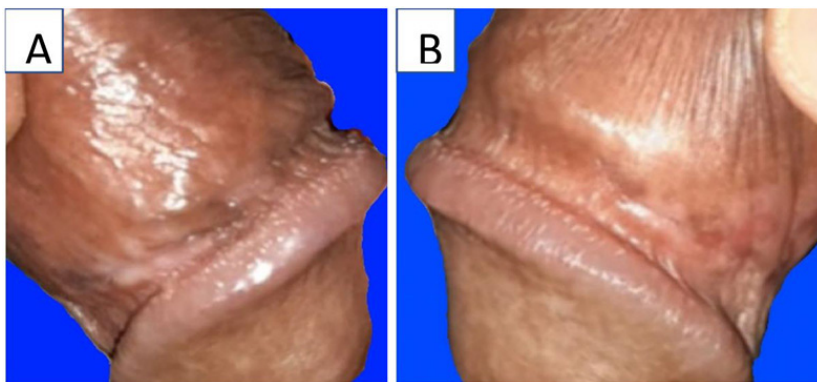
wound appeared. Complaints of pain were heavier, accompanied by exudates of clear fluid and pus that came out of the wound. The skin around the wound was erythematous and swollen. The patient also had a fever and a swelling in the left groin. The patient has never experienced a similar condition.

The last sexual intercourse was seven days before the wound appeared, anogenital intercourse, penetrative partner, and without a condom. The patient said that there was no complaint of pain or injury to the genitals and anus in the partner. Last intercourse was in August 2019 (seven months earlier) with a male boyfriend, and he had only been with one sex partner for two years. The patient's partner had also been diagnosed with AIDS and died in September 2019.

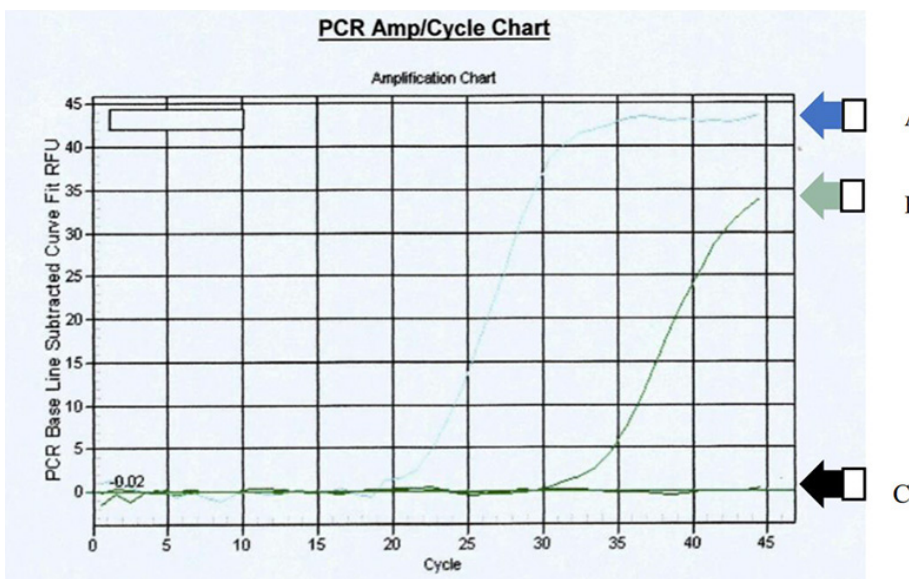
The patient was diagnosed with HIV in 2013 at RSCM. The patient received ARV therapy zidovudine, lamivudine, and



**Figure 1.** Dorso-lateral coronary sulcus region: superficial, multiple ulcers (before therapy).



**Figure 2.** Hypopigmented macular-ectrophic scar lesions post-therapy acyclovir 3x400 mg (10 days) and co-amoxiclav 3x625 mg (7 days).



**Figure 3.** Real-time positive HSV PCR examination results. Sample curve (A), positive control (B), negative control (C)

nevirapine, but the patient only drank less than a month and then stopped because of side effects of nausea and inability to eat. The patient dropped out of drugs from 2013 to 2016. The patient returned to treatment in 2016 with ARV and anti-tuberculosis drugs (ATD) for one year (2017). The CD4 count in October 2019 was 122 cells/ $\mu$ L. The patient is currently taking the drug Truvada® (tenofovir and emtricitabine) 1x1 tablet, Aluvia® (ritonavir and lopinavir) 1x1 tablet, Hiviral® (lamivudine) 1x1 tablet, and cotrimoxazole 1x960 mg.

On physical examination, the vital signs were within normal limits. The venereology status of the coronary sulcus on the dorso-lateral side showed multiple superficial, irregular, confluence ulcers, size 0.4 x 0.2 x 0.1 cm. 1.5 x 1.2 x 0.1 cm, non-risen edges, non-sloping wall, dirty base filled with pus, pain (visual analog scale = 3-4), on palpation, there is no induration (Figure 1. A, B). There was an enlarged lymph node on the left inguinal, rubbery, size 2 x 2 x 0.7 cm, no tenderness, and free from the underlying tissue.

Smear examination from the ulcer base specimen with gram stain obtained leukocytes polymorphonuclear (PMN) >30/binocular visual field (bvf), gram-positive cocci 20-25/bvf, and no gram-negative rod bacteria found. This patient's working diagnosis was genital ulcer *et causa* suspected first genital herpes with secondary infection. The patient received acyclovir 3x400 mg for ten days and co-amoxiclav 3x625 mg for seven days.

Serological examination of IgM HSV-1, IgM HSV-2, IgG HSV-2, VDRL, and TPHA were non-reactive, whereas IgG HSV-1 was reactive with a titer of 5.05 CO. Real-time PCR HSV examination was positive. (Figure 3). Examination of smears of post-treatment ulcer base specimens seven days with gram stain. The leukocyte count was reduced to 3-4/bvf, 3-4 gram-positive cocci bacteria/bvf, and no gram-negative rod bacteria were found. The patient was diagnosed with improved non-primary initial GH, and the secondary infection was cured. Acyclovir 3x400 mg was continued for up to ten days, while co-amoxiclav stopped. On the 10th day of treatment, there were marked improvements in wounds and complaints

of pain, and in physical examination, found eutrophic scars to hypopigmented macules on coronary sulcus. The patient was then declared cured (**Figure 2. A, B**).

## DISCUSSION

The diagnosis of GH is determined by history, physical examination, and laboratory examinations. History and physical examination related to complaints of genital lesions, including the number and type of lesions, size, edge, depth, base, induration, pain, and the onset of the wound.<sup>3</sup> The atypical clinical features of GH are found in immunocompromised conditions, for example, patients with HIV/AIDS, malignancy, and transplantation.<sup>4-6</sup> Atypical lesions in GH, including hyperkeratotic, vegetative, and necrotic ulcers, with wider size and slow healing. The lesions can also appear in other locations, including the buttocks and back.<sup>5-8</sup> The patient has a burning, painful ulcer in the coronary sulcus. This ulcer-like lesion is one of the atypical features of GH, so it needs to be differentiated from other genital ulcers.

Laboratory tests for GH consist of serological, cytological, antigen detection viruses, virus culture, molecular biology, and examination by Western blot method, enzymes immune assay (EIA), enzyme-linked immunosorbent assay (ELISA), and immunofixation.<sup>2,9</sup> Laboratory tests performed in this case were serological and molecular biology (rPCR).

In this case, there is a clinical picture of acute infection with atypical lesions. The United States Centers for Disease Control and Prevention (CDC) recommends anti-HSV serologic testing for recurrent or atypical clinical symptoms with negative PCR or culture results.<sup>2</sup> Our serological examination in this patient was IgG HSV-1 reactive while IgG HSV-2, IgM HSV-1, and HSV-2 are non-reactive. Reactive HSV IgM antibody means acute infection or recurrent infection, whereas the HSV IgG antibody indicates previous HSV exposure.<sup>9</sup> There is a discrepancy between the patient's clinical symptoms and the results of the serological examination. A study of the prevalence of HSV serology in an HIV-positive population with GH in India showed only 3.8% reactive results for HSV-1 IgM and 34.6% HSV-2 IgM, while

94.2% for HSV-1 IgG and HSV-2 IgG 61.5%.<sup>10</sup> HSV IgM seroconversion begins at six weeks and decreases after more than 12 weeks post-infection. Examinations carried out during the "window period" before IgM formation will yield false-negative results.<sup>11</sup> The HSV IgM examination is no longer recommended as a routine laboratory examination.<sup>9</sup>

The patient's HSV rPCR examination was positive. The rPCR examination specimen was taken from the ulcer base, then put into a 0.9% NaCl transport medium and sent to the laboratory within 2 hours. Real-time PCR is a part of molecular biology testing currently growing, but not all laboratories have rPCR facilities. The PCR sensitivity value was 98%, and the specificity was 100%. The limitation of the rPCR examination in RSCM is that it cannot determine the type of HSV. HSV type determination is vital for the prognosis of GH. On serological analysis, reactive results were obtained on IgG HSV-1. Herpes simplex virus-1 is the etiology of GH in 50% of cases of first-episode GH. Subclinical recurrence and viral shedding were less common with HSV-1 infection than with HSV-2.<sup>9</sup>

There is a discrepancy in the results of serological examination and PCR in patients, but the diagnosis of GH can be made, and management should not be delayed. 3x400 mg acyclovir therapy is given for up to ten days. Observations on the tenth-day patient no longer complained of pain, and the wound has considerably healed. One case report of a patient with atypical GH in HIV infection showed that delayed diagnosis and treatment result in lesion enlargement and prolonged healing.<sup>12</sup> The skin lesions at the beginning were multiple ulcers in the pubis, penile body, and upper 1/3 of the scrotum, later diagnosed with a non-specific genital ulcer. Six months later, the wound worsened, extending to the upper limbs bilaterally on the medial side. In this case, lesion improvement was achieved after the patient took acyclovir 5x400 mg for 14 days. Acyclovir is a first-line antiviral drug for treating HSV infection, including GH, but the limitation of acyclovir is a low oral bioavailability ranging from 15% to 30%. For severe GH infection and immunocompromised patients, therapy

can be given intravenously.<sup>12,13</sup> In this case, oral acyclovir was used, and it showed a significant improvement of the lesion.

## CONCLUSION

In this patient, atypical clinical findings, with a non-supportive serological examination, whereas the PCR result was positive and significant clinical improvement after therapy. The selection and accurate interpretation of investigations play a crucial role in the diagnosis of HG. Discrepancies in examination results can occur, but this discrepancy must be addressed carefully so that there is no delay in diagnosis and management. Early diagnosis of GH in patients with HIV infection can prevent the worsening of the disease.

## ETHICS IN PUBLICATION

Informed consent was explained and signed by the patient.

## CONFLICT OF INTEREST

None.

## FUNDING

None.

## AUTHOR CONTRIBUTIONS

All authors contributed to the case, literature, and publication of this case report.

## REFERENCES

1. Groves MJ. Genital herpes: a review. *Am Fam Physician*. 2016;93(11):928–34.
2. Frieden TR, Harold Jaffe DW, Rasmussen SA, Leahy MA, Martinroe JC, Spriggs SR, et al. Genital ulcer adenopathy. In: *Sexually Transmitted Diseases Treatment Guidelines*. New York: CDC; 2015. p. 1–140.
3. Ballard C. Genital ulcer adenopathy. In: Holmes K, Sparling P, Stamm W, Piot P, Wasserheit J, Corey L, editors. *Sexually Transmitted Diseases* 4th edition. New York: McGraw-Hill; 2008. p. 1199–209.
4. Bonita L, Dwi M. Gambaran Klinis Herpes Simpleks Genitalis ( A Retrospective Study : Clinical Manifestation of Genital Herpes Infection ). *Period Dermatology Venereol*. 2017;29(1):30–5.
5. Sauerbrei A. Herpes Genitalis: Diagnosis, Treatment and Prevention. *GbFra Sci*. 2016;76(12):1310–7.

6. Cag Y, Erdem H, Leib S, Defres S, Kaya S, Larsen L, et al. Managing atypical and typical herpetic central nervous system infections: results of a multinational study. *Clin Microbiol Infect.* 2016;22(6):568.e9-568.e17.
7. McKendry A, Narayana S, Browne R. Atypical presentations of genital herpes simplex virus in HIV-1 and HIV-2 effectively treated by imiquimod. *Int J STD AIDS.* 2015;26(6):441-3.
8. Nilasari H, Lumintang H. Infeksi herpes simpleks pada pasien HIV/AIDS. In: Hidayati A, Daili S, Niode N, Indriatmi W, Budiono S, Barakbah J, editors. *Manifestasi dan Tatalaksana Kelainan Kulit dan Kelamin Pada Pasien HIV/AIDS.* Jakarta: Badan Penerbit FKUI; 2018. p. 53-65.
9. Legoff J, Péré H, Bélec L. Diagnosis of genital herpes simplex virus infection in the clinical laboratory. *Virol J.* 2014;11(1):1-17.
10. Nag S, Sarkar S, Chattopadhyay D, Bhattacharya S, Biswas R, Sengupta M. Seroprevalence of Herpes Simplex Virus Infection in HIV Coinfected Individuals in Eastern India with Risk Factor Analysis. *Adv Virol.* 2015;2015:1-7.
11. Clementi N, Cappelletti F, Criscuolo E, Castelli M, Mancini N, Burioni R, et al. Role and potential therapeutic use of antibodies against herpetic infections. *Clin Microbiol Infect.* 2017;23(6):381-6. Available from: <http://dx.doi.org/10.1016/j.cmi.2016.12.023>
12. Istasaputri K, Djajakusumah TS, Rachmadinata, R. Rowawi. Herpes Genitalis dengan Gambaran Klinis tidak Khas pada Penderita AIDS. *Glob Med Heal Commun.* 2013;1(1):24-30.
13. Barroso dos Reis HL, Tosato Boldrini NA, da Silva Campos LC, Campos LG, Salume Costa FL, Jacomele Caldas JV, et al. Hypertrophic genital herpes in an HIV-infected female patient: Imiquimod as an alternative treatment. *Int J Infect Dis.* 2020;95:153-6.



This work is licensed under a Creative Commons Attribution