



Published by
Department of Dermatology and
Venereology, Universitas Udayana



CrossMark

Challenges of limited treatment options in suspected antimicrobial resistance of multibacillary Hansen's disease with chronic erythema nodosum leprosum: a case report and literature review

Agrevina Ane Lukito^{1*}, I Ketut Suteja Wibawa^{2,3},
I Komang Harry Supradnyan^{2,3}

ABSTRACT

Background: Hansen's disease, or leprosy, is a chronic infection caused by *Mycobacterium leprae* that affects the skin and peripheral nerves. The emergence of antimicrobial resistance in leprosy poses a new challenge, potentially reducing treatment efficacy and increasing the risk of relapse. Recent studies report recurrent or chronic erythema nodosum leprosum (ENL) cases linked to relapse caused by drug-resistant *Mycobacterium leprae* strains. This case report aimed to emphasize the knowledge and therapeutic approach of leprosy and leprosy reaction.

Case Description: A 51-year-old female patient previously treated for multibacillary (MB) leprosy and declared released from treatment (RFT) a year earlier, presented with painful erythematous nodules on all extremities two months after RFT. Eight months after RFT, the patient developed new erythematous macules with loss of sensation on all extremities, consistent with leprosy relapse. Multi-drug therapy (MDT) was subsequently re-initiated. During follow-up, laboratory evaluation indicated a high bacterial load, raising suspicion of antimicrobial resistance. The patient was initiated on the regimen for leprosy with antimicrobial resistance. However, the complete regimen could not be provided immediately due to medication limitations in the remote region.

Conclusion: Antimicrobial resistance in leprosy should be considered in patients with relapse who do not respond to MDT re-treatment and in those with chronic ENL. Limited availability of resistance testing resources and access to second-line therapies remain a significant barrier to the effective management of antimicrobial resistance leprosy.

Keywords: Antimicrobial resistance, erythema nodosum leprosum, leprosy, leprosy relapse, multibacillary leprosy.

Cite This Article: Lukito AA, Wibawa IKS, Supradnyana IKH. Challenges of limited treatment options in suspected antimicrobial resistance of multibacillary Hansen's disease with chronic erythema nodosum leprosum: a case report and literature review. Bali Dermatology Venereology and Aesthetic Journal. 2025;8(2): 37-40.

DOI: 10.51559/balidervenaesthj.v8i2.120

¹Faculty of Medicine and Health Science,
Atma Jaya Catholic University of
Indonesia

²Department of Dermatology,
Venereology, and Aesthetic, Buleleng
General Hospital, Indonesia

³Faculty of Medicine, Pendidikan
Ganesha University, Indonesia

*Corresponding author:

Agrevina Ane Lukito; Faculty of Medicine
and Health Science, Atma Jaya Catholic
University of Indonesia;
Phone: +6281238966949
agrevinaanelukito17@gmail.com

Submitted: 2025-12-04

Accepted : 2025-12-30

Published: 2025-12-31

INTRODUCTION

Hansen's disease, also known as leprosy, is a chronic infection caused by the acid-fast bacillus complex *Mycobacterium leprae*.¹ Leprosy primarily affects the skin and peripheral nerves.² According to data from the World Health Organization (WHO), there were 182,815 new cases of leprosy reported globally in 2023, with Brazil, India, and Indonesia together contributing 79.3% of global new cases. Furthermore, 2,040 cases of antimicrobial resistance were reported by 12 countries, including Brazil and Indonesia.³ Antimicrobial resistance complicates treatment regimens, increases the risk of serious complications,

and contributes to treatment failure. Drug-resistant *M. leprae* strains are also associated with a higher likelihood of relapse.⁴ Currently, relapse cases of leprosy remain a global public health issue, with one of the causes linked to antimicrobial resistance, particularly in patients with multibacillary leprosy.⁵ This case report aims to increase knowledge and awareness of leprosy treatment and leprosy reactions.

CASE DESCRIPTION

A 51-year-old female with a history of multibacillary (MB) leprosy received multi-drug therapy (MDT) and was declared released from treatment (RFT)

a year prior. At the time of RFT, the bacteriological index (BI) was 2+ / 1+ on the right and left earlobes and 1+ on all four extremities. Two months later, the patient developed erythema nodosum leprosum (ENL), presenting with multiple painful erythematous nodules on all extremities. The patient was initiated on methylprednisolone, with gradual dose tapering according to clinical response, which was ongoing at the time of evaluation.

Eight months post-RFT, the patient reported new erythematous macules with loss of sensation on all extremities, consistent with relapse, and MDT-MB

was re-initiated. After four months of therapy, a slit-skin smear revealed a BI of 5+/4+ on the right and left earlobes, respectively (Figure 1), and 1+/1+/2+/3+ across the extremities. Due to poor clinical response to MDT and the unavailability of laboratory antimicrobial resistance testing, the patient was clinically suspected to have antimicrobial resistance. She was subsequently started on antimicrobial-resistant leprosy treatment with ofloxacin and clofazimine, without clarithromycin or minocycline, as these drugs were not available in the region. Minocycline was later obtained from another district and added to the regimen after one month of treatment. Following one month of combined therapy including minocycline, a repeat slit-skin smear demonstrated a BI of 1+ and 3+ on the right and left earlobes, respectively, and -/-/1+/- on the extremities (Table 1). The clinical progression at 4 months after MDT re-initiation and 2 months after the initiation of antimicrobial resistance therapy is shown in Figure 2.

The patient continued routine follow-up visits, reporting gradual improvement. There were no new erythematous macules with loss of sensation or painful erythematous nodules. After two months of clinical improvement, follow-up was referred back to primary health care.

DISCUSSION

Hansen’s disease, or leprosy, is an infectious disease caused by *Mycobacterium leprae*, characterized by skin and peripheral nerve involvement and a risk of permanent disability if untreated. Leprosy is classified as a neglected tropical disease by the World Health Organization (WHO) because it primarily affects poor communities with inadequate housing and sanitation, overcrowding, and limited access to health care services.⁶ According to the World Health Organization (WHO), 182,815 new cases of leprosy were reported globally in 2023. In the same year, WHO documented 2,040 cases of antimicrobial resistance across 12 countries, including Brazil and Indonesia, which included 2 cases of rifampicin resistance, 20 of dapsone resistance, and 19 of ofloxacin resistance.³ Antimicrobial resistance has emerged as a significant challenge in leprosy treatment,

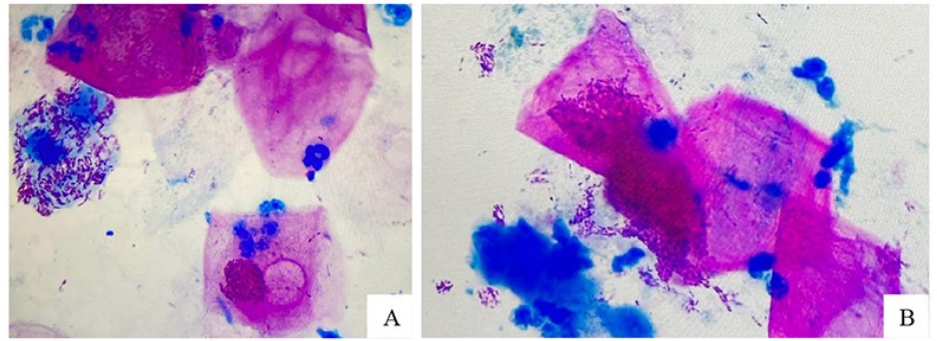


Figure 1. Acid-fast bacilli (AFB) in earlobes slit-skin smear, 4 months post-MDT re-initiation, suggestive of antimicrobial resistance: right earlobe (A) and left earlobe (B).

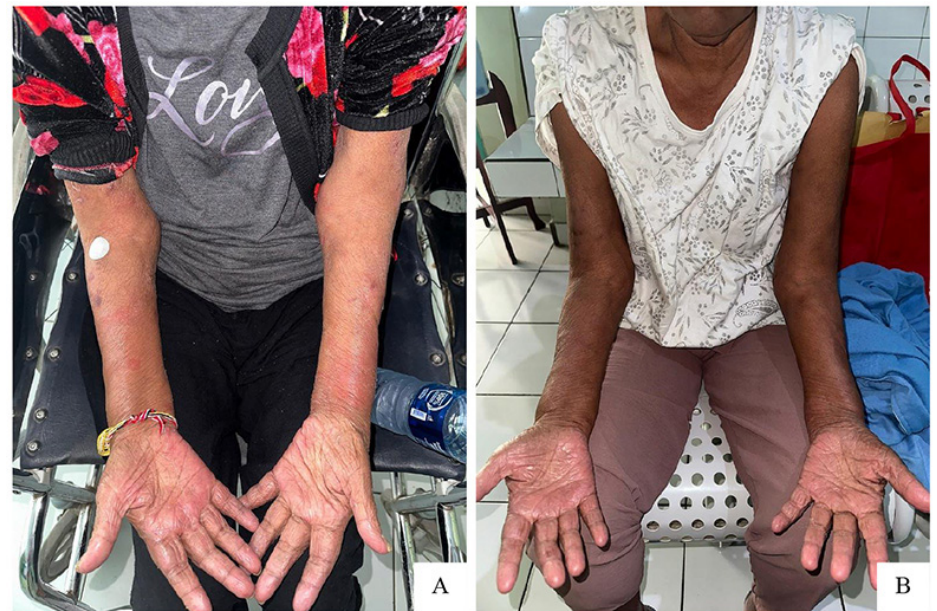

Figure 2. Clinical presentation: 4 months post-MDT re-initiation (A), and after 2 months of antimicrobial-resistant treatment (B).

Table 1. Acid-Fast Bacilli (AFB) smear results at different treatment stages

Time Point	Earlobes	Extremities
Pre-treatment (RFT)	2+/1+	1+/1+/1+/1+
4 months post-MDT re-initiation	5+/4+	1+/1+/2+/3+
2 months of AMR treatment	1+/3+	-/-/1+/-

AFB = Acid-fast bacilli; MDT = Multi-drug therapy; RFT = Released from treatment; AMR = Antimicrobial Resistance.

as it can lead to treatment failure, prolonged therapy, and increased healthcare costs. Resistance is more frequently observed in patients with relapse compared to new cases. The emergence of drug-resistant *M. leprae* not only complicates the treatment of affected individuals but also threatens the achievement of leprosy eradication goals due to the spread of resistant strains within the community.⁴

Multibacillary (MB) leprosy is associated with a higher risk of antimicrobial resistance compared with paucibacillary (PB) leprosy, largely due to the higher bacterial load that increases the chance of selecting resistant *M. leprae* strains. Longer duration and more intensive treatment in MB cases also contribute to this risk, as prolonged antimicrobial exposure in a high bacterial

load environment can promote the emergence of resistance. Relapse further heightens this concern, since repeated exposure to antimicrobial agents can facilitate the expansion of resistant strains. It should also be noted that incomplete or irregular treatment may contribute to the development of antimicrobial resistance. These factors align with the general principles of antimicrobial resistance, in which sustained or repeated antimicrobial exposure allows bacteria to develop survival mechanisms against the specific antimicrobial agent involved.⁷ Recent studies report that recurrent or chronic erythema nodosum leprosum (ENL) cases are linked to relapse caused by drug-resistant *Mycobacterium leprae* strains.⁸ Other studies indicate that patients with chronic or recurrent ENL may harbor hidden drug resistance, yet they often respond well to second-line anti-leprosy therapy.⁹ Chronic ENL is also more frequently observed in individuals of productive age, those with ENL onset before MDT, or among ENL patients with coinfections.¹⁰

Our patient has a history of MB leprosy and has been receiving treatment for chronic ENL for the past 10 months. The patient later reported the reappearance of leprosy symptoms after being declared released from treatment, consistent with relapse. There was no indication of treatment non-adherence. Therefore, the most likely factors contributing to the suspected antimicrobial resistance were the patient's prior MB leprosy that required prolonged MDT and the additional course of MDT-MB administered during the four months before the current presentation. In addition, the patient's chronic ENL is consistent with studies reporting that chronic ENL may be associated with underlying, unrecognized antimicrobial resistance. This supports the possibility that the patient's chronic ENL may represent a suspected antimicrobial-resistant state.

WHO recommends antimicrobial resistance testing for all relapse cases of leprosy and for samples from new or retreatment MB cases, with the aim of detecting resistance to rifampicin, dapsone, and ofloxacin, and to monitoring

resistance trends over time.^{11,12} The 2017 WHO Surveillance of Drug Resistance in Leprosy Guidelines further specify that testing is required to detect primary resistance in new cases and secondary resistance in retreatment cases. All retreatment patients should be tested, except "transferred-in" cases, unless there is concern for incomplete or irregular prior treatment. Testing is performed on skin-slit smears or skin biopsies using polymerase chain reaction (PCR) method and is limited to MB patients with a BI of $\geq 2+$, as these samples have a higher likelihood of yielding a positive PCR result.¹²

Our patient was an MB relapse case who had undergone MDT retreatment. After four months of retreatment, AFB evaluation showed a BI of 5+/4+ on both earlobes, meeting WHO criteria for secondary resistance testing using PCR. However, testing could not be performed due to the unavailability of PCR-based antimicrobial resistance diagnostics in the region. As a result, antimicrobial resistance could not be confirmed, and the patient was managed as a suspected case of antimicrobial resistance leprosy.

The WHO guidelines for rifampicin-resistant leprosy recommend the use of two second-line drugs (clarithromycin, minocycline, or a quinolone) plus clofazimine for 6 months, followed by clofazimine in combination with one second-line drug for an additional 18 months. In the presence of ofloxacin resistance, fluoroquinolones should not be included in second-line therapy.¹³ Our patient was suspected to have antimicrobial resistance, with no history of ofloxacin treatment. Therefore, the patient was planned to receive treatment with the WHO-recommended regimen for rifampicin-resistant leprosy. However, clarithromycin and minocycline were not available in the region. Due to limited access to medications, the initial treatment included only ofloxacin and clofazimine. Through efforts to obtain the medicine from a larger district, the patient was able to access minocycline after one month, resulting in clinical improvement and reduced BI.

CONCLUSION

This case highlights the need to consider antimicrobial resistance in patients with chronic ENL or relapsed leprosy who do not respond to MDT. This case also highlights the challenges of managing suspected antimicrobial resistance leprosy in resource-limited settings, where resistance testing and access to WHO-recommended second-line drugs are often unavailable. Early recognition of potential resistance and improved availability of second-line agents are crucial for optimizing patient outcomes.

CONFLICT OF INTEREST

There is no personal, financial, or institutional conflict of interest regarding this article.

ETHICS IN PUBLICATION

This case report complies with ethical standards of medical publication, and written informed consent was obtained from the patient.

FUNDING

None.

AUTHOR CONTRIBUTIONS

All authors contributed equally to the clinical management of the case, literature review, manuscript preparation, and the overall development of this publication. All authors reviewed and approved the final manuscript.

GENERATIVE ARTIFICIAL INTELLIGENCE (AI) DISCLOSURE

The author declares that there was no involvement of AI in the writing of this manuscript.

REFERENCES

1. Maymone MBC, Laughter M, Venkatesh S, Dacso MM, Rao PN, Stryjewska BM, et al. Leprosy: Clinical aspects and diagnostic techniques. *Journal of the American Academy of Dermatology*. 2020;83(1):1–14. DOI: [10.1016/j.jaad.2019.12.080](https://doi.org/10.1016/j.jaad.2019.12.080)
2. Lazo-Porras M, Prutsky GJ, Barrionuevo P, Tapia JC, Ugarte-Gil C, Ponce OJ, et al. World Health Organization (WHO) antibiotic regimen

- against other regimens for the treatment of leprosy: a systematic review and meta-analysis. *BMC Infect Dis.* 2020;20(1):62. DOI: [10.1186/s12879-019-4665-0](https://doi.org/10.1186/s12879-019-4665-0)
3. World Health Organization. Global leprosy (Hansen disease) update, 2023: Elimination of leprosy disease is possible – Time to act! 2024 (Internet). *Wkly Epidemiol Rec* 2024 (Accessed on November 11th 2025);99:501-21. Available from: <https://www.who.int/publications/i/item/who-wer9937-501-521>
 4. Lukito AA, Paralaga IBKB, Supradnyan IKH. The growing threat of antimicrobial resistance in *Mycobacterium leprae*: A literature review. *Intisari Sains Medis.* 2024;15(3):1324–32. DOI: [10.15562/ism.v15i3.2202](https://doi.org/10.15562/ism.v15i3.2202)
 5. Li X, Li G, Yang J, Jin G, Shao Y, Li Y, et al. Drug Resistance (Dapsone, Rifampicin, Ofloxacin) and Resistance-Related Gene Mutation Features in Leprosy Patients: A Systematic Review and Meta-Analysis. *IJMS.* 2022;23(20):12443. DOI: [10.3390/ijms232012443](https://doi.org/10.3390/ijms232012443)
 6. Yotsu RR, Miyamoto Y, Mori S, Ato M, Sugawara-Mikami M, Yamaguchi S, et al. Hansen's disease (leprosy) in Japan, 1947-2020: an epidemiologic study during the declining phase to elimination. *International Journal of Infectious Diseases.* 2022;125:265–74. DOI: [10.1016/j.ijid.2022.10.027](https://doi.org/10.1016/j.ijid.2022.10.027)
 7. Zivarifar H, Ahrari F, Karbalaeei M. Computational investigation of the global prevalence of multidrug resistant *Mycobacterium leprae*: A systematic review and meta-analysis. *Journal of Clinical Tuberculosis and Other Mycobacterial Diseases.* 2024;37:100495. DOI: [10.1016/j.jctube.2024.100495](https://doi.org/10.1016/j.jctube.2024.100495)
 8. Bhat R, Vaidya T. What is new in the pathogenesis and management of erythema nodosum leprosum. *Indian Dermatol Online J.* 2020;11(4):482. DOI: [10.4103/idoj.IDOJ_561_19](https://doi.org/10.4103/idoj.IDOJ_561_19)
 9. Jindal R, Singh I, Bhardwaj S, Chauhan P. High Prevalence of Resistance to Anti-Leprosy Drugs in Leprosy Cases with Chronic Erythema Nodosum Leprosum: A Matter of Concern. *Indian Dermatology Online Journal.* 2022;13(4):511–3. DOI: [10.4103/idoj.idoj_581_21](https://doi.org/10.4103/idoj.idoj_581_21)
 10. Indrawati D, Astari L, Hidayati AN, Sawitri S, Damayanti D, Utomo B, et al. Risk Factors of Acute and Chronic Erythema Nodosum Leprosum in Dr. Soetomo General Academic Hospital Surabaya. *Pharmacogn J.* 2023;14(6):766–70. DOI: [10.5530/pj.2022.14.165](https://doi.org/10.5530/pj.2022.14.165)
 11. World Health Organization. Towards Zero Leprosy Global Leprosy (Hansen's disease) Strategy 2021–2030. New Delhi: World Health Organization. 2021:1-30.
 12. World Health Organization. A Guide for Surveillance of Antimicrobial Resistance in Leprosy. Regional Office for South-East Asia: World Health Organization. 2017:1-56.
 13. World Health Organization. Guidelines for the Diagnosis, Treatment and Prevention of Leprosy. New Delhi: World Health Organization. 2018:1-87.



This work is licensed under a Creative Commons Attribution